



PATIENT

Hank Estes

SPECIES

Canine

BREED

Hound Mix

SEX

Male Neutered

AGE

1 year

WEIGHT

66lbs

PRESENTING CLINICAL SIGNS

History: Hank is referred to evaluate a heart murmur. He is doing well with no clinical issues. On exam: NSR, grade I/VI murmur with PMI left apical area, PSS, lung fields clear, mm pink, moist, CRT<2. BP: 130mmHg x 5. No medications. *Sedated with propofol for study.

ECHOCARDIOGRAM FINDINGS

2D, m-mode, color flow and Doppler imaging is available.

Left ventricle: The LV diameter is normal with adequate myocardial function. LV wall thicknesses are normal.

Left atrium: The left atrium is normal.

Mitral valve: The mitral valve is mildly thickened with no prolapse into the left atrial lumen. No mitral regurgitation.

Aortic valve/Aorta: The aortic valve is normal in morphology and mobility. Normal aortic outflow velocity; laminar flow. No aortic insufficiency.

Right ventricle: Normal right ventricular diameter and morphology indicating no overt evidence of pulmonary arterial hypertension.

Right atrium: Normal RA dimension.

Tricuspid valve: The tricuspid valve appears normal with no tricuspid regurgitation.

Pulmonic valve/Pulmonary artery: The pulmonic valve is normal in morphology and mobility. No pulmonic insufficiency. Normal RVOT velocity; laminar flow.

Pericardium/other: No pericardial or pleural effusion noted. No obvious cardiac masses.

Heart rhythm: ECG reveals a sinus rhythm with an average HR of 100bpm.

2-Dimensional Measurements

Ao diam (cm)	2.5
LA diam (cm)	3.0
LA:Ao (Swe)	1.2
IVS thickness (cm)	1.0
LVID diastole (cm)	4.4
PW thickness (cm)	1.0
LVID systole (cm)	3.0
FS (%)	32

Doppler Measurements

PV Vmax (m/s)	0.9
AoV Vmax (m/s)	1.4
MR Vmax (m/s)	NA
TR Vmax (m/s)	NA
TR PG (mmHg)	NA

INTERPRETED BY

Maggie Machen
Lamy, DVM
DACVIM (Cardiology)

IMAGING PERFORMED BY

Pamela Harrigan,
RDCS

HOSPITAL NAME

Mass Veterinary Services

REFERRING VET

Dr. Masloski

INVOICE

28080

DATE

1/4/23

INTERPRETATION OF THE FINDINGS

Overtly normal cardiac structure and function. No cause of the murmur is identified in this study. In the absence of significant volume changes (dehydration) or anemia, other possibilities include a physiologic flow murmur only present with elevated heart rates, or a small flow abnormality not seen here. It is reasonable to monitor periodically via recheck echocardiography in the future, particularly should the murmur persist/progress. No significant valvular insufficiencies were noted, and no structural issues identified.

RECOMMENDATIONS

- No cardiac medications are indicated at this time.
- Monitor for any development of cough, labored breathing or exercise intolerance.
- No cardiac contraindication for general anesthesia.

PLAN

- Recommend recheck echocardiogram in 12 months to screen for progression or development of concurrent cardiac disease that the preexisting murmur may mask.



PATIENT

Hank Estes

SPECIES

Canine

BREED

Hound Mix

SEX

Male Neutered

AGE

1 year

WEIGHT

66lbs

INTERPRETED BY

Maggie Machen
Lamy, DVM
DACVIM (Cardiology)

**IMAGING
PERFORMED BY**

Pamela Harrigan,
RDCS

HOSPITAL NAME

Mass Veterinary
Services

REFERRING VET

Dr. Masloski

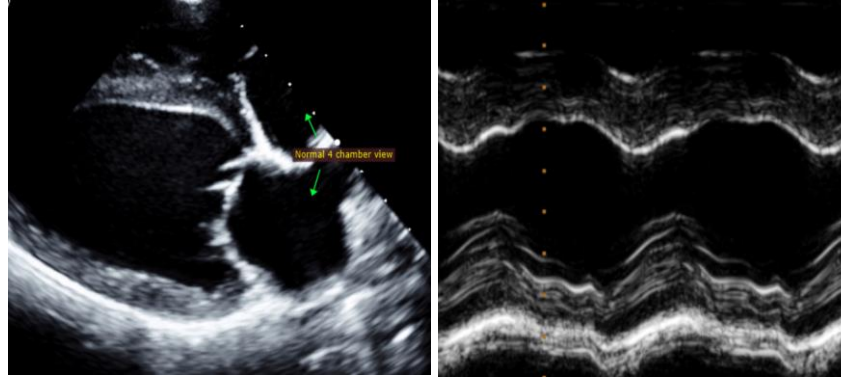
INVOICE

28080

DATE

1/4/23

IMAGES



The information and recommendations provided are based on the images presented by the referring veterinarian. No evaluation can be communicated regarding pathology that was not visible in the image/video clips provided.

Thank you for this referral. This report was generated using transcription software, and minor dictation errors may be present. If the clinical or image interpretation does not parallel your findings or if I can be of any further assistance, please contact me.

Maggie Machen Lamy, DVM
Diplomate of the American College of Veterinary Internal Medicine (Cardiology)
info@sonopath.com

Echocardiogram performed by:

Pamela Harrigan, RDCS
Pet Animal Ultrasound Service (4paus.com)